

Properties and function of the Flexor Hallucis Capsularis

Interphalangeus tendon

Llewellyn Thomas¹, Jan Herman Kuiper^{2,3} and Timothy Knight³

1) Plastic Surgery Department, Derriford Hospital, Plymouth, United Kingdom;
2) Institute for Science and Technology in Medicine, Keele University, Staffordshire, United Kingdom; 3) The Robert Jones and Agnes Hunt Orthopaedic Hospital, NHS Foundation Trust, Oswestry, United Kingdom

Published as: Thomas RL, Kuiper JH, Knight TP. Properties and function of the Flexor Hallucis Capsularis Interphalangeus tendon. *Clinical Anatomy* 2019 Oct 3. doi:10.1002/ca.23490

Abstract

The fibrocartilagenous plantar plates of the forefoot are biomechanically important, forming the primary distal attachment for the plantar aponeurosis. They are integral to the function of the windlass mechanism in supporting the arches of the foot in gait. Dissection of the cadaveric hallux revealed an organised sagittal thickening of the dorsal side of the Flexor Hallucis Longus (FHL) sheath, which attached the interphalangeal plantar plate to the metatarsophalangeal (MTP) plantar plate. A description of a similar structure was made by McCarthy et al. in 1984 when it was termed the Flexor Hallucis Capsularis Interphalangeus (FHCI) – however, it has not been researched since, and we aim to study it further and identify its characteristics.

Methods

Eight specimens were dissected from four cadavers. Two were stained and examined under microscope and both polarized and non polarized light. The remaining 6 were subjected to micrometer testing of their tensile properties.

Results

Both the histological features and mechanical properties were consistent with tendon like substance, with cross sectional area, ultimate tensile strength and stiffness varying between specimens.

Conclusions

Based on its location and properties, the FHCI tendon may be involved in limiting dorsiflexion of the first MTP joint and could have clinical relevance in pathological processes around both the first and second MTP joints.

Introduction

Whilst injuries of the plantar plates of the forefoot have been well discussed and there have been recent articles detailing relevant biomechanics and pathophysiology (Bolgia and Malone, 2004; Carlson et al., 2000; Frimenko et al., 2012; Myerson and Badekas, 2000; Sarrafian, 1987; Shereff et al., 1986), the anatomy of the plantar plates of the hallux has not been subject to recent review. Several articles concentrate on the plantar plates of the lesser digits (Deland et al., 1995; Johnston et al., 1994). The plantar plates of the forefoot are part of the joint capsule of the metatarsophalangeal (MTP) and interphalangeal (IP) joints. Whilst of a similar nature to the volar plates of the hand, the fibrocartilaginous plantar plates are subject to far greater compressive and tensile forces (Johnston et al., 1994). Their form reflects this, being robust with a strong distal insertion (Deland et al., 1995). The MTP plantar plates have several noteworthy attachments. These are to each other via the deep transverse metatarsal ligament; to the flexor sheath and joint capsule with which they are continuous; and to the plantar aponeurosis via strong vertically oriented fibers (Deland et al., 1995; Stainsby, 1997). This last attachment is recognized as forming the most biomechanically relevant distal attachment of the plantar aponeurosis (Stainsby, 1997). The first MTP plantar plate differs in that it is associated with two sesamoid bones, and its flexor tendon sheath encases only the

tendon of flexor hallucis longus (FHL). The two sesamoid bones form the distal attachment of flexor hallucis brevis (FHB).

Originally described in Hicks' seminal work of 1954, the windlass mechanism places the aponeurosis in the role of a tie-bar with the medial longitudinal arch of the foot as the truss' arch (Hicks, 1954). When the foot is loaded whilst standing, the aponeurosis acts as a tension band and flattens slightly as the arch takes weight. (Lapidus, 1963) However, in the last stages of the stance phase of gait; namely heel rise, push off and toe off, the windlass mechanism approaches maximum activation. Dorsiflexion of the first MTP joint leads to the 1st MTP joint plantar plate being pulled forward around the metatarsal head (Sarrafian, 1987). This was described by Kelikian as a dynamic acetabulum or 'hammock' (Kelikian, 1966) with several centres of motion (Hetherington et al., 1989). In turn, this exerts force on the vertical fibers of the aponeurosis, recruiting the windlass mechanism (Caravaggi et al., 2009; Carlson et al., 2000). The tension across the aponeurosis is increased, and this actively heightens and compresses the arch to make it a more stable weight-bearing platform. The lesser toes fulfil the same function, but most of the force is transmitted through the hallux (Hicks, 1954); if there is a lack of active plantar flexion of the hallux MTP joint during take-off, forward motion is less efficient (Stefanyshyn and Nigg, 1997). The strong distal attachment for the hallux MTP joint plantar plate has been described as being solely into the proximal phalanx. The authors have found no mention of the IP plantar plate of the hallux playing a role in the windlass mechanism. Clinically, there are several relevant conditions related to pathology around the 1st MTP joint. These include sprains ('turf toe'), hallux valgus and hallux rigidus (Myerson and Badekas, 2000).

During dissection, a structure was encountered within the flexor sheath of FHL, between the MTP and IP plantar plates of the hallux, formed of a thickening of the flexor sheath immediately deep to the tendon of flexor hallucis longus (Figure 1, Figure 2). This affixed the MTP plantar plate to the IP plantar plate. The appearance was consistent with a sagittally oriented band of tendon-like tissue, which was qualitatively able to withstand significant longitudinal tensile forces (Figure 3, Figure 4). This was not seen in the lesser MTP joints. A literature search was performed using the MeSH terms 'hallux', 'anatomy', 'biomechanics', and 'plantar plate' in a MEDLINE search using PubMed. There was no mention of such a structure in recent radiological anatomy reviews (Schein et al., 2015) but it seems an original description can be ascribed to McCarthy et al. in the Journal of the American Podiatric Medical Association who suggested the name 'Flexor Hallucis Capsularis Interphalangeus' (FHCI) (McCarthy et al., 1986). This was included in McGlamry's (McGlamry et al., 1992), but no quantitative study of its nature has been performed. The objective of this study was therefore to assess the nature and biomechanical properties of this structure, answering three questions.

1. What are its structural properties?
2. What is its purpose and what are the biomechanical implications?
3. Is this clinically relevant?

Materials and Methods

Using anonymized fresh frozen cadaveric specimens, eight feet from four cadavers were dissected. The sagittal slips were identified and isolated. These were then removed from their proximal and distal attachments for testing.

The cross sectional areas were calculated from the specimens' width and height measuring using digital Vernier calipers (M11015DDL, Moore & Wright, Sheffield, UK) Calipers were used in order to avoid specimen deformation encountered with area micrometry (Woo et al., 1990). One specimen was discarded at this stage as unsuitable. The specimens were then stored as frozen specimens once again in order to preserve their characteristics as much as possible (Fessel et al., 2011; Viidik and Lewin, 1966).

The remaining seven specimens were then individually fixed onto an electromechanical universal testing machine (100-Q-225-6, TestResources Inc, Shacopee, MN, USA) using sandpaper and hand-tightened clamps. We aimed for a starting distance (zero-length) of 10 mm between the clamps. All tests were recorded on video and analyzed afterwards to determine the actual zero-length of each specimen and to look for signs of tissue slippage from the clamps during testing. Preconditioning was then conducted by applying 10 displacement cycles to 0.5 mm at a rate of 0.1 mm/sec to improve the quality of subsequent testing (Schatzmann et al., 1998).

Immediately following the cyclical preconditioning, the specimens were subjected to a quasi-static test by applying displacement at a rate of 0.1mm/sec until failure. Strain was calculated from the deformation of the specimen as measured by the testing machine in relation to the zero-length. The stress values were calculated

using the pre-testing cross sectional area of each specimen. Stress-strain graphs were then plotted to assess the Young's modulus of each specimen as the slope of the linear part of the stress-strain curve. The ultimate tensile stress (UTS) was determined as the maximum stress before failure.

Two specimens, one 50mm in length and one 55mm in length, were used for a histological investigation. They were embedded in wax, sectioned and stained with hematoxylin and eosin. The stained sections were viewed under polarized and non-polarized light at x6.3 and x25 magnification (Figure 5).

Results

Quasistatic Testing:

The mean cross-sectional area was 2.00 mm² (SD 1.86, range 0.64 to 5.66; see Table for details). The mean maximum load during quasistatic testing was 50.6 N (SD 22.5, range 21.9 to 80.2). The mean UTS was 36.6 MPa (SD 23.9, range 11.8 to 71.2). The mean Young's modulus was 206 MPa (SD 136, range 50 to 403). The results from one sample were discarded due to clamp failure. These results are demonstrated in **Table 1**.

Histology:

The specimens had longitudinally arranged parallel collagenous fibers. A layer of tendon sheath was apparent, consistent with the intimacy to the FHL tendon

sheath. Scattered fibroblasts were seen. Overall, microscopy of these two samples confirmed the appearance of the tissue as consistent with tendon, with a parallel array of collagen fibers and an inner layer of tendon sheath apparent.

Discussion

The purpose of this study was to further describe the FHCI tendon and to answer the three questions delineated in the introduction. We have identified that histologically and biomechanically the slip is consistent with tendon, and that there is a great degree of variability between individuals within this small sample size. The stress testing results showed a large amount of variation within the data sets, which did not have a clear correlation with the dimensions of the samples which we tested.

What are its structural properties?

The mechanical characteristics (mean Young's modulus 206 MPa, mean tensile strength 36.6 MPa) were consistent with those found for tendons (Ethier and Simmons, 2007; Martin et al., 1998). The stress-strain curves derived from the data demonstrated a wide variability of characteristics between the specimens (Figure 9). Such wide variations, even between specimens from the left and right foot, have also been found in other studies, for example a study of ankle ligaments (Louis-Ugbo et al., 2004; Siegler et al., 1988) or Achilles tendons (Louis-Ugbo et al., 2004; Siegler et al., 1988). Tendons and ligaments differ throughout the body in their elasticity and tensile strength according to their collagen content, elastin content and calcification (Ethier and Simmons, 2007; Landis and Silver, 2002; Martin et al., 1998). The

difference we found between the specimens may reflect the differences in the demographics of our cadavers. However, it cannot be excluded that imperfections in our dissection and clamping technique may have further increased the variability. As a consequence, it is difficult to draw epidemiological conclusions regarding the strength of the slip from this data set.

What is its biomechanical purpose?

Relating the windlass mechanism to the sagittal slip, several possibilities can be considered. The IP joint of the hallux has been quoted as having a passive range of motion of approximately 31 degrees (Salleh et al., 2005). It is possible that FHCI is an accessory structure which allows force to be transmitted more efficiently through the hallux by reinforcing it in a sagittal plane during MCPJ dorsiflexion. There are no muscular attachments to FHCI. This implies that the FHCI tendon, the insertion of the PP into the proximal phalanx and FHL act in concert with the windlass mechanism to prevent hyperextension of the 1st MTP joint. The insertion of the MTP plantar plates into the proximal phalanges is the strongest distal attachment of the windlass mechanism (Deland et al., 1995). It has been postulated that the first MTPJ is more involved in the windlass mechanism than the others (Hicks, 1954); if so, FHCI may only be present in the hallux due to the increased forces placed across the hallux during dorsiflexion. Variety in the composition and tensile properties of FHCI may be determined by fibroblastic activity in response to loading (Nawoczenski et al., 1999).

There have been few studies related to the premorbid degree of 1st MTP joint laxity in relation to the incidence rate of injuries in the area, although it has been

discussed that excess dorsiflexion around the 1st MTP joint can cause a hypermobile first ray (Bouche and Heit, 2008). This has further implications, implying that excessive dorsiflexion around the 1st MTP joint could predispose to a variety of conditions in the area. Hypermobility of the first ray itself has also been associated with many conditions, including hallux valgus and metatarsus primus varus (Rush et al., 2000), with laxity around the 1st MTP joint increasing the relevance in relation to the FHCI tendon (Myerson and Badekas, 2000; Roukis et al., 1996).

Further possibilities can be considered in regard to the increased laxity in dorsiflexion around the 1st MTP joint. Relevant conditions include 1st MTP joint sprain ('turf toe') and hallux rigidus, which has been linked to 1st ray hypermobility (Kunnasegaran and Thevendran, 2015), among other pathologies (Lucas and Hunt, 2015; Shereff and Baumhauer, 1998). If the wider biomechanical implications of first ray hypermobility are considered, other conditions become relevant; such as injuries to the second metatarsal head, rupture of the 2nd metatarsal plantar plate and Freiberg's disease. However, study of these processes would incorporate many variables and would be difficult to perform.

Hallux valgus has been linked with first ray hypermobility (Wong et al., 2014) although it is a matter of contention which of the two is the causative pathology (Doty and Coughlin, 2013); it is probable that this is multifactorial in combination with other biomechanical abnormalities (Perera et al., 2011). There is ongoing discussion regarding the aetiology of hallux valgus, contradicting Morton and Lapidus' original works (Glasoe and Coughlin, 2006; Hansen, 1996; Lapidus, 1963), and hypothesizing secondary biomechanical effects would be conjecture.

Is this clinically relevant?

First MTP joint pathology

Athletes are the highest risk group for MTP joint sprain or 'turf toe'; in these injuries the mechanism is hyperextension at the first MTPJ in up to 85%, causing disruption of the plantar plate and its sesamoids (Bowers and Martin, 1976; Rodeo et al., 1990). Even in mild cases this injury can be debilitating for the athlete, as dorsiflexion is painful during the recovery period (Kubitz, 2003; McCormick and Anderson, 2010b). Injury to the FHCI may be a feature of MTP joint sprain. There are chronic sequelae associated with the injury, including an increased risk of recurrence, incomplete recovery and long-term stiffness (McCormick and Anderson, 2010a). An injury at this site can reduce an athlete's acceleration and mobility in the long term, due to impairment of biomechanical efficiency (Brophy et al., 2009; Coughlin et al., 2010; Frimenko et al., 2012).

There is little scope for operative intervention in mild 'turf toe' injuries, but in severe or chronic injuries this can be an option (Coughlin et al., 2010; McCormick and Anderson, 2009). Conservative management for 'turf toe' currently depends on the severity of the injury, but early physical therapy and mobilization is sometimes advised in milder forms (Coker et al., 1978; McCormick and Anderson, 2010b). It is difficult to recommend a change in practice based on the findings of this study.

Second MTP joint pathology

Metatarsalgia of the second MTPJ is a common presentation and has several differentials, including plantar plate rupture and Freiberg's infarction (Shane et al.,

2013). Pathology around the second metatarsal head has been ascribed to increased pressure in this area during gait (Cho et al., 2013; Klein et al., 2013; Shane et al., 2013). It rarely occurs in seclusion and is often linked with other biomechanical abnormalities, including a hypermobile first ray and hallux valgus (Ahn et al., 2016; Coughlin, 1993; Lee et al., 2014). Repetitive trauma and perfusion abnormalities have also been implicated (Katcherian, 1994), and hypermobile dorsiflexion of the 1st MTPJ leading to increased pressure on the second metatarsal could be a predisposing factor.

Limitations

This study suffered from several limitations. Firstly, our testing of the central part of the slip does not assess the nature of the whole structure. During specimen collection, the FCHI tendons were dissected out from their attachments to the plantar plates. As a consequence, we could assess their biomechanical properties only through clamping the ends of the specimens. A more accurate assessment of *in vivo* function would have been to include bone and use this to hold the specimens while applying forces. Secondly, the cross-sectional area was determined using calipers, however when measuring tendons discrepancies have been reported between testing methods (Woo et al., 1990). Thirdly, it would be useful to determine the histological nature of FCHI insertion into the plantar plates, in addition to those of the central material. One sample was rendered unsuitable for testing by the collection process and another slipped through the clamps. The number of samples and the age range of the subjects was not sufficient to study the influence of age or other demographic factors on the structure or mechanical properties of the slip. The

difference between the results of specimens from the same cadaver may indicate a true difference but could also be due to shortcomings in our methodology.

Conclusion

Our findings are consistent with the FHCI tendon having variability in its properties between individuals, but that it is robust enough to have real biomechanical implications. Histological assessment confirms that the FHCI is functional tendon, with assessment of tensile strength and elasticity supporting this. The function of FHCI may be related to gait, in particular dorsiflexion around the hallucal MTP joint. It is possible that this may predispose to 1st ray hypermobility with the attendant pathological correlations. We believe there are several conditions that could be affected by dysfunction of this structure, but that it is difficult to recommend a change to practice based on our current findings.

Bibliography

- Ahn J, Lee HS, Seo JH, Kim JY. 2016. Second Metatarsal Transfer Lesions Due to First Metatarsal Shortening After Distal Chevron Metatarsal Osteotomy for Hallux Valgus. *Foot Ankle Int*.
- Bolgia LA, Malone TR. 2004. Plantar fasciitis and the windlass mechanism: a biomechanical link to clinical practice. *J Athl Train* 39:77-82.
- Bouche RT, Heit EJ. 2008. Combined plantar plate and hammertoe repair with flexor digitorum longus tendon transfer for chronic, severe sagittal plane instability of the lesser metatarsophalangeal joints: preliminary observations. *J Foot Ankle Surg* 47:125-137.
- Bowers KD, Jr., Martin RB. 1976. Turf-toe: a shoe-surface related football injury. *Med Sci Sports* 8:81-83.
- Brophy RH, Gamradt SC, Ellis SJ, Barnes RP, Rodeo SA, Warren RF, Hillstrom H. 2009. Effect of turf toe on foot contact pressures in professional American football players. *Foot Ankle Int* 30:405-409.
- Caravaggi P, Pataky T, Goulermas JY, Savage R, Crompton R. 2009. A dynamic model of the windlass mechanism of the foot: evidence for early stance phase preloading of the plantar aponeurosis. *J Exp Biol* 212:2491-2499.
- Carlson RE, Fleming LL, Hutton WC. 2000. The biomechanical relationship between the tendoachilles, plantar fascia and metatarsophalangeal joint dorsiflexion angle. *Foot Ankle Int* 21:18-25.
- Cho J, Kim JR, Lee WC. 2013. Degenerative osteoarthritis of the second metatarsophalangeal joint: second toe rigidus. *Int Orthop* 37:1863-1869.
- Coker TP, Arnold JA, Weber DL. 1978. Traumatic lesions of the metatarsophalangeal joint of the great toe in athletes. *Am J Sports Med* 6:326-334.
- Coughlin MJ. 1993. Second metatarsophalangeal joint instability in the athlete. *Foot Ankle* 14:309-319.
- Coughlin MJ, Kemp TJ, Hirose CB. 2010. Turf toe: soft tissue and osteocartilaginous injury to the first metatarsophalangeal joint. *Phys Sportsmed* 38:91-100.
- Deland JT, Lee KT, Sobel M, DiCarlo EF. 1995. Anatomy of the plantar plate and its attachments in the lesser metatarsal phalangeal joint. *Foot Ankle Int* 16:480-486.
- Donegan RJ, Caminear D. 2016. Anatomic Repair of Plantar Plate With Flexor Tendon Sheath Reinforcement: Case Series. *Foot Ankle Spec* 9:438-443.
- Doty JF, Coughlin MJ. 2013. Hallux valgus and hypermobility of the first ray: facts and fiction. *Int Orthop* 37:1655-1660.
- Duan X, Li L, Wei DQ, Liu M, Yu X, Xu Z, Long Y, Xiang Z. 2017. Role of magnetic resonance imaging versus ultrasound for detection of plantar plate tear. *J Orthop Surg Res* 12:14.
- Ethier CR, Simmons CA. 2007. Introductory biomechanics from cells to organisms. In: *Cambridge texts in biomedical engineering*. Cambridge ; New York: Cambridge University Press. p xiii, 511 p., [516] p. of plates.
- Fessel G, Frey K, Schweizer A, Calcagni M, Ullrich O, Snedeker JG. 2011. Suitability of Thiel embalmed tendons for biomechanical investigation. *Ann Anat* 193:237-241.
- Frimenko RE, Lievers W, Coughlin MJ, Anderson RB, Crandall JR, Kent RW. 2012. Etiology and biomechanics of first metatarsophalangeal joint sprains (turf toe) in athletes. *Crit Rev Biomed Eng* 40:43-61.
- Glasoe WM, Coughlin MJ. 2006. A critical analysis of Dudley Morton's concept of disordered foot function. *J Foot Ankle Surg* 45:147-155.

- Gregg J, Silberstein M, Schneider T, Marks P. 2006. Sonographic and MRI evaluation of the plantar plate: A prospective study. *Eur Radiol* 16:2661-2669.
- Hansen ST, Jr. 1996. Hallux valgus surgery. Morton and Lapidus were right! *Clin Podiatr Med Surg* 13:347-354.
- Hetherington VJ, Carnett J, Patterson BA. 1989. Motion of the first metatarsophalangeal joint. *J Foot Surg* 28:13-19.
- Hicks JH. 1954. The mechanics of the foot. II. The plantar aponeurosis and the arch. *J Anat* 88:25-30.
- Johnston RB, 3rd, Smith J, Daniels T. 1994. The plantar plate of the lesser toes: an anatomical study in human cadavers. *Foot Ankle Int* 15:276-282.
- Katcherian DA. 1994. Treatment of Freiberg's disease. *Orthop Clin North Am* 25:69-81.
- Kelikian H. 1966. Hallux Valgus, Allied Deformities of the Forefoot, and Metatarsalgia. *American Journal of the Medical Sciences* 251:116.
- Klein EE, Weil L, Jr., Weil LS, Sr., Knight J. 2013. The underlying osseous deformity in plantar plate tears: a radiographic analysis. *Foot Ankle Spec* 6:108-118.
- Kubitz ER. 2003. Athletic injuries of the first metatarsophalangeal joint. *J Am Podiatr Med Assoc* 93:325-332.
- Kunnasegaran R, Thevendran G. 2015. Hallux Rigidus: Nonoperative Treatment and Orthotics. *Foot Ankle Clin* 20:401-412.
- Landis WJ, Silver FH. 2002. The structure and function of normally mineralizing avian tendons. *Comp Biochem Physiol A Mol Integr Physiol* 133:1135-1157.
- Lapidus PW. 1963. Kinesiology and mechanical anatomy of the tarsal joints. *Clin Orthop Relat Res* 30:20-36.
- Lee KT, Park YU, Jegal H, Young KW, Kim JS, Lim SY. 2014. Osteoarthritis of the second metatarsophalangeal joint associated with hallux valgus deformity. *Foot Ankle Int* 35:1329-1333.
- Louis-Ugbo J, Leeson B, Hutton WC. 2004. Tensile properties of fresh human calcaneal (Achilles) tendons. *Clin Anat* 17:30-35.
- Lucas DE, Hunt KJ. 2015. Hallux Rigidus: Relevant Anatomy and Pathophysiology. *Foot Ankle Clin* 20:381-389.
- Martin RB, Burr DB, Sharkey NA. 1998. *Skeletal tissue mechanics*. New York: Springer.
- McCarthy DJ, Reed T, Abell N. 1986. The hallucal interphalangeal sesamoid. *J Am Podiatr Med Assoc* 76:311-319.
- McCormick JJ, Anderson RB. 2009. The great toe: failed turf toe, chronic turf toe, and complicated sesamoid injuries. *Foot Ankle Clin* 14:135-150.
- McCormick JJ, Anderson RB. 2010a. Rehabilitation following turf toe injury and plantar plate repair. *Clin Sports Med* 29:313-323, ix.
- McCormick JJ, Anderson RB. 2010b. Turf toe: anatomy, diagnosis, and treatment. *Sports Health* 2:487-494.
- McGlamry ED, Banks AS, Downey MS. 1992. *Comprehensive textbook of foot surgery*, 2nd ed. Baltimore: Williams & Wilkins.
- Moraes do Carmo CC, Fonseca de Almeida Melao LI, Valle de Lemos Weber MF, Trudell D, Resnick D. 2008. Anatomical features of plantar aponeurosis: cadaveric study using ultrasonography and magnetic resonance imaging. *Skeletal Radiol* 37:929-935.
- Myerson MS, Badekas A. 2000. Hypermobility of the first ray. *Foot Ankle Clin* 5:469-484.
- Nawoczenski DA, Baumhauer JF, Umberger BR. 1999. Relationship between clinical measurements and motion of the first metatarsophalangeal joint during gait. *J Bone Joint Surg Am* 81:370-376.
- Perera AM, Mason L, Stephens MM. 2011. The pathogenesis of hallux valgus. *J Bone Joint Surg Am* 93:1650-1661.

- Rodeo SA, O'Brien S, Warren RF, Barnes R, Wickiewicz TL, Dillingham MF. 1990. Turf-toe: an analysis of metatarsophalangeal joint sprains in professional football players. *Am J Sports Med* 18:280-285.
- Roukis TS, Scherer PR, Anderson CF. 1996. Position of the first ray and motion of the first metatarsophalangeal joint. *J Am Podiatr Med Assoc* 86:538-546.
- Rush SM, Christensen JC, Johnson CH. 2000. Biomechanics of the first ray. Part II: Metatarsus primus varus as a cause of hypermobility. A three-dimensional kinematic analysis in a cadaver model. *J Foot Ankle Surg* 39:68-77.
- Salleh R, Beischer A, Edwards WH. 2005. Disorders of the hallucal interphalangeal joint. *Foot Ankle Clin* 10:129-140.
- Sarrafiian SK. 1987. Functional characteristics of the foot and plantar aponeurosis under tibiotalar loading. *Foot Ankle* 8:4-18.
- Schatzmann L, Brunner P, Staubli HU. 1998. Effect of cyclic preconditioning on the tensile properties of human quadriceps tendons and patellar ligaments. *Knee Surg Sports Traumatol Arthrosc* 6 Suppl 1:S56-61.
- Schein AJ, Skalski MR, Patel DB, White EA, Lundquist R, Gottsegen CJ, Forrester DM, Matcuk GR, Jr. 2015. Turf toe and sesamoiditis: what the radiologist needs to know. *Clin Imaging* 39:380-389.
- Shane A, Reeves C, Wobst G, Thurston P. 2013. Second metatarsophalangeal joint pathology and freiberg disease. *Clin Podiatr Med Surg* 30:313-325.
- Shereff MJ, Baumhauer JF. 1998. Hallux rigidus and osteoarthritis of the first metatarsophalangeal joint. *J Bone Joint Surg Am* 80:898-908.
- Shereff MJ, Bejjani FJ, Kummer FJ. 1986. Kinematics of the first metatarsophalangeal joint. *J Bone Joint Surg Am* 68:392-398.
- Siegler S, Block J, Schneck CD. 1988. The mechanical characteristics of the collateral ligaments of the human ankle joint. *Foot Ankle* 8:234-242.
- Stainsby GD. 1997. Pathological anatomy and dynamic effect of the displaced plantar plate and the importance of the integrity of the plantar plate-deep transverse metatarsal ligament tie-bar. *Ann R Coll Surg Engl* 79:58-68.
- Stefanyshyn DJ, Nigg BM. 1997. Mechanical energy contribution of the metatarsophalangeal joint to running and sprinting. *J Biomech* 30:1081-1085.
- Viidik A, Lewin T. 1966. Changes in tensile strength characteristics and histology of rabbit ligaments induced by different modes of postmortal storage. *Acta Orthop Scand* 37:141-155.
- Wong DW, Zhang M, Yu J, Leung AK. 2014. Biomechanics of first ray hypermobility: an investigation on joint force during walking using finite element analysis. *Med Eng Phys* 36:1388-1393.
- Woo SL, Danto MI, Ohland KJ, Lee TQ, Newton PO. 1990. The use of a laser micrometer system to determine the cross-sectional shape and area of ligaments: a comparative study with two existing methods. *J Biomech Eng* 112:426-431.

Figure captions

Figure 1 – The FHCI tendon is identified deep to flexor hallucis longus

Figure 2 – The tendon is discrete from the joint capsule

Figure 3 – FHCI appears robust in this specimen

Figure 4 – FHCI appears able to withstand tensile forces

Figure 5 – Histological assessment revealed tendon with an inner layer of tendon sheath.

Table 1 – Mechanical characteristics of dissected ligamentous structure

Specimen	X-sectional area (mm ²)	QS max Load (N)	UTS (MPa)	Young's Modulus (MPa)
140066L	1.85	21.9	11.8	47.2.5
140066R	0.64	45.6	71.8	275.6
140148L	1.06	63.6	57.7	403.4
140148R	1.83	63.6	34.7	232.8
140062R	5.66	80.2	14.2	58.9.7
140156R	0.98	28.9	29.6	179.9
Mean (SD)	2.00 (1.86)	50.6 (22.5)	36.6 (23.9)	199 (135)

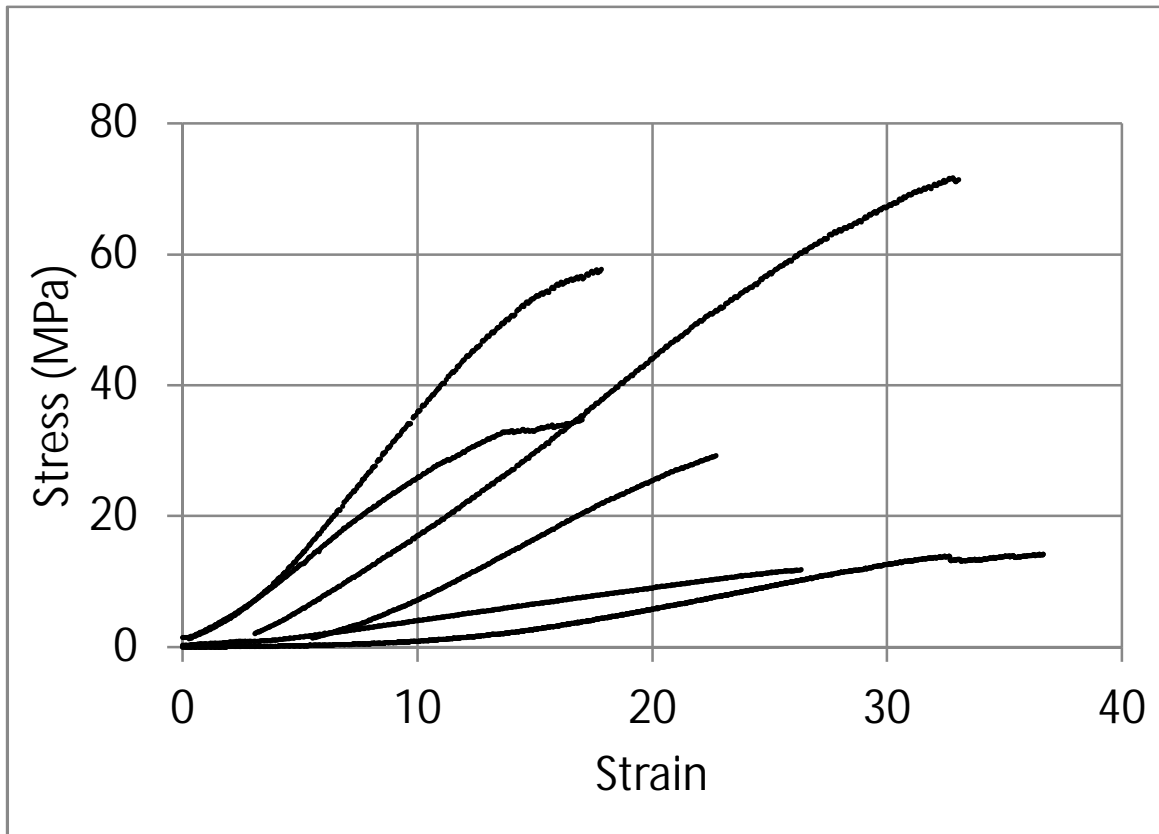


Table 2 – Stress - strain relationships for specimens

